

Right common carotid a. _____

Right subclavian a. _____

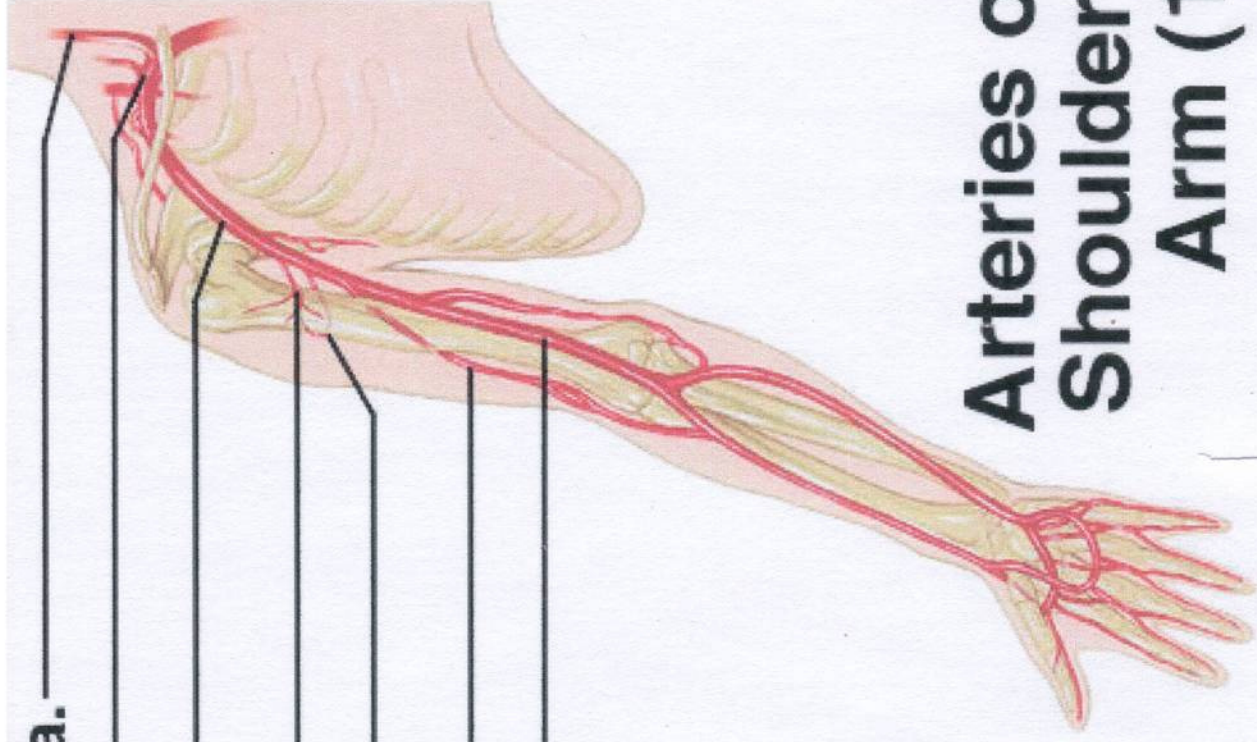
Axillary a. _____

Anterior circumflex a. _____

Posterior circumflex a. _____

Deep brachial a. _____

Brachial a. _____



Arteries of Shoulder Arm (1)